



CLINICAL AND CYTOGENETIC CHARACTERIZATION OF A PATIENT WITH TETRASOMY 18P

CARACTERIZACIÓN CLÍNICA Y CITOGENÉTICA DE UN PACIENTE CON TETRASOMÍA 18P

Vazquez Cantu D.L.^{1,2}, Gutiérrez García V.M.², Cruz Camino H.^{1,4}, Lara Díaz V.J.², Garza García K.², Garduño L.M.³, Meléndez R.³, Paz A.⁴, Mayén D.G.⁴, Cantú Reyna C.^{1,2,*}

¹Genomi-k S.A.P.I. de C.V., Monterrey, Nuevo León, México.

²Escuela de Medicina Tecnológico de Monterrey, Monterrey, Nuevo León, México.

³Unidad de Genética, Hospital Ángeles Lomas, Estado de México, México.

⁴Escuela de Biotecnología y Ciencias de la Salud, Tecnológico de Monterrey, Monterrey, México.

* Corresponding Author: cocantu@genomi-k.com

ABSTRACT

The 18p tetrasomy is a structural chromosomal abnormality with the presence of an extra isochromosome 18p, caused by a nondisjunction failure during maternal meiosis II. This additional i(18p) occurs in 1 of 180,000 live-born children worldwide, and affects males and females equally. It is characterized by craniofacial dysmorphisms; ears, nose and throat (ENT) abnormalities; musculoskeletal alterations; and global development delay. We aim to present the clinical and cytogenetic findings of a 3-year-10-month-old Latin American male with i(18p), to support the gene dosage effects, comparing his features with the ones reported in literature. This patient was product of the second pregnancy of a 39-year-old woman and the first son of a 49-year-old man. His main clinical features were microcephaly, facial dysmorphism, generalized hypotonia, and developmental delay. A blood sample of the patient was required to perform a GTG-banded karyotype and a fluorescence *in situ* hybridization (FISH) for chromosome 18 short arm. In addition, an SNP microarray analysis was carried out to detect genomic imbalances. Cytogenetic analysis revealed the presence of a metacentric supernumerary marker chromosome. The FISH study confirmed the origin of the marker chromosome by showing two signals for the 18p subtelomere and an intermediate signal for the 18 centromere. The microarray analysis showed a copy number gain of 18,385 Mb within the 18p. Tetrasomy tends to be a result of *de novo* events. The presence of the patient's isochromosome could be explained by advanced maternal age as it is known that this factor has high influence in isochromosome formation. Despite that there were no genes associated with the i(18p)'s clinical manifestations, these features are negatively correlated with dosage effects of the entire short arm. Physical and language therapy was recommended to the patient; the family received medical orientation, and awareness in family planning was raised.

Key words: tetrasomy 18p, chromosome 18, isochromosome, cytogenetic analysis, case report

RESUMEN

La tetrasomía 18p es una anomalía cromosómica estructural con la presencia de un isocromosoma extra 18p, causado por una no disyunción durante la meiosis materna II. Este adicional i(18p) ocurre en 1 de 180.000 niños nacidos vivos en todo el mundo, y afecta a hombres y mujeres por igual. Se caracteriza por dismorfismos craneofaciales; anomalías en oídos, nariz y garganta (ENT); alteraciones musculoesqueléticas y del desarrollo global. Nuestro objetivo es presentar los hallazgos clínicos y citogenéticos de un varón latinoamericano de 3 años y 10 meses de edad con i(18p), para respaldar los efectos de dosificación génica, comparando sus características con las reportadas en la literatura. Este paciente es producto del segundo embarazo de una mujer de 39 años y el primer hijo de un hombre de 49 años. Sus principales características clínicas fueron microcefalia, dismorfismo facial, hipotonía generalizada y retraso en el desarrollo. Se requirió una muestra de sangre del paciente para realizar un cariotipo con bandas GTG y una hibridación fluorescente *in situ* (FISH) para el análisis del brazo corto del cromosoma 18. Además, se llevó a cabo un análisis de microarreglos para detectar desequilibrios genómicos. El análisis citogenético reveló la presencia de un cromosoma supernumerario metacéntrico. Mientras que el estudio FISH confirma el origen del cromosoma marcador al mostrar dos señales para subtelómeros 18p y una señal intermedia para el centrómero 18. El análisis de microarreglos mostró una ganancia en el número de copias de 18,385 Mb dentro de las 18p. La tetrasomía tiende a ser el resultado de eventos *de novo*. El isocromosoma del paciente podría explicarse por la edad materna avanzada, ya que se sabe que tiene una gran influencia en la formación de isocromosomas. A pesar de que no hay genes asociados con las manifestaciones clínicas de i(18p), estas características están negativamente correlacionadas con los efectos de dosificación de todo el brazo corto. Se le recomendó terapia física y de lenguaje al paciente, la familia recibió orientación médica y se concientiza sobre la planificación familiar.

Palabras clave: tetrasomía 18p, cromosoma 18, isocromosoma, análisis citogenético, reporte de caso clínico

INTRODUCCIÓN

An 18p isochromosome results from a nondisjunction failure and a centromeric misdivision during meiosis II, first described in 1963 by Froland *et al.* When the isochromosome is supernumerary, the result is a tetrasomy. Nowadays, the incidence of the 18p tetrasomy has been reported in 1:180,000 live-born children worldwide, tending to be a result of *de novo* events (Dutra *et al.*, 2012; Plaiasu *et al.*, 2011). Based on the accumulated environmental and age-related effects on women's meiotic machinery, the increase proportion of nondisjunction in older population pregnancies can be explained (Dutra *et al.*, 2012; Froland *et al.*, 1963).

The structural arrangement on the chromosome, coupled with overexpression of genes results on craniofacial dysmorphism, characterized by ophthalmologic, high nasal bridge, long philtrum, micrognathia, prognathism, and highly arched palate. Hearing loss and recurrent otitis media are often presented, as well as orthopedic abnormalities and a global developmental delay (Callen *et al.*, 1990; Chen *et al.*, 2014; Zavala *et al.*, 2009; Wei *et al.*, 2015; Sebold *et al.*, 2010; Nusbaum *et al.*, 2015).

Despite that chromosome 18 has the lowest gene density of any human chromosome, it represents approximately 2.7% of the human genome. For a proper diagnosis, cytogenetic testing is needed, connoted by fluorescence *in situ* hybridization (FISH), multiplex ligation-dependent probe amplification (MLPA), and comparative genomic hybridization (CGH) (Wei *et al.*, 2015).

We aim to present the clinical and molecular cytogenetic findings in a 3-year-10-month-old Latin American male with i(18p), to support the genotype-phenotype dosage effects, comparing his clinical features with the ones reported in literature.

CASE REPORT

A 3-year-10-month-old male patient (Figure 1), product of the second pregnancy of a 39-year-old woman and the first son of a 49-year-old man -both healthy and non-consanguineous- was referred to genetic counseling. The obstetric antecedents showed an uncomplicated pregnancy, completed prenatal care, and an eutocic delivery; the patient's weight at birth was 2,750 g and 49 cm of length. There were no reports of repeated abortions

or malformations neither in the family history nor in close relatives.

The cephalic support was achieved at the age of 6 months, seating was achieved six months later, and the beginning of ambulation started at the age of 3 years. At the time of genetic counseling, the patient was unable to speak and could not control sphincters. He presented neonatal respiratory distress syndrome at birth, remaining in the intensive care unit for 15 days; and suffered from gastroesophageal reflux during the first 6 months of life.

At physical examination, microcephaly, narrow forehead with mild prominence in the area of the metopic suture, mild left palpebral ptosis, antimongoloid palpebral fissures, narrow and bulbous nose, long philtrum, thin lips, high palate, and macrognathia were identified. Also, he presented low implantation of auricular pavilions and short neck, multiple folds in hands and feet, thumb tending to adduction, and generalized hypotonia (Table 1, Figure 2 and 3). Ophthalmological and audiological assessment did not report an associated pathology. The electroencephalogram, echocardiogram, and renal ultrasound were reported normal.

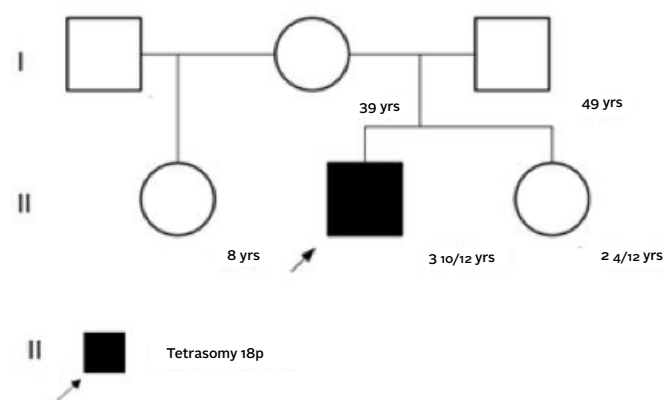


Figure 1. The family pedigree of a 3-year-10-month-old male (index case II, 2) from the second gestation of a 39-year-old woman and the first son of a 49-year-old man.

Table 1. Clinical features of patients reported with i(18p) compared with the index patient.

Features	P1 ³	P2 ³	P3 ³	P4 ³	P5 ³	P6 ³	P7 ³	P8 ³	P9 ³	Index P
Age at review	7 wk	16 mo	21 mo	7 yr	11 yr	13 yr	23 yr	30 yr	36 yr	3 yr
Sex	F	F	M	F	F	F	F	F	F	M
Parental age in yrs (mother:father)	36:22	31:34	37:43	34:30	29:28	26:26	35:35	39:41	36:4 6	38:48
<i>Growth:</i>										
Birth weight (g)	2,500	2,250	2,580	2,860	3,260	2,130	2,355	2,950	3,630	2,750
Height (per)	3	10	3-10	3	3	10	<3	10	<3	25-50
Head circumference (per)	10	<3	50	<3	3	<3	<3	<3	3	NK
<i>Developmental delay</i>	MOD - SEV	MOD	MOD	SEV	MOD	MILD -SEV	MOD	MILD -MOD	SEV	MOD
<i>Neonatal Feeding difficulties</i>	+	+	+	-	NK	+	+	-	NK	+
<i>Ophthalmologic</i>										
Strabismus	-	-	+	+	+	+	+	+	-	-
<i>ENT abnormalities</i>										
Low-set ears	-	+	+	+	-	+	+	-	+	+
High Nasal Bridge	-	-	-	-	-	-	+	+	+	+
Micrognathia	+	+	+	+	-	+	-	-	-	+
Prognathism	-	-	-	+	-	+	+	+	+	+
High arched palate	+	-	-	-	+	-	-	+	-	+
Large philtrum	+	+	+	+	NK	+	-	-	-	+
<i>Neurological</i>										
Seizures	+	-	-	+	+	+	+	-	-	-
Spasticity	+	+	+	+	+	+	+	+	+	-
<i>Orthopedic</i>										
Camptodactyly	+	+	-	-	-	-	-	-	+	-
Scoliosis/kyphosis	-	-	-	-	-	+	+	-	+	+
Adducted thumbs	+	+	-	-	+	-	-	-	-	-

³ P: patient, wk: weeks, mo: months, yr: years, F: female, M: male, g: grams, per: percentile, MOD: moderate, SEV: severe, NK: not known, +: present, -: not present.

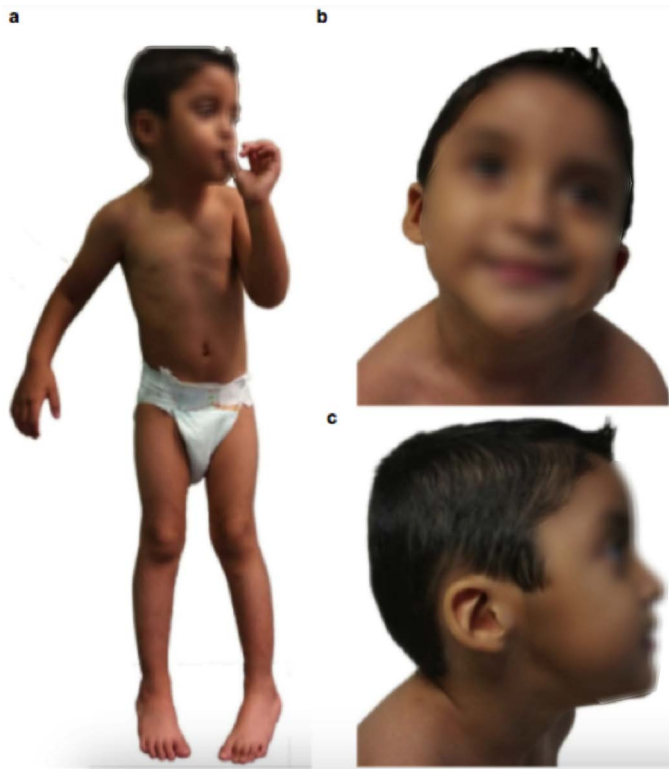

Figure 2. a) Full-body image showing scoliosis and low-set ears. b) front view remarking high nasal bridge and large philtrum c) lateral view showing low-set, malformed ears, micrognathia and prognathism.

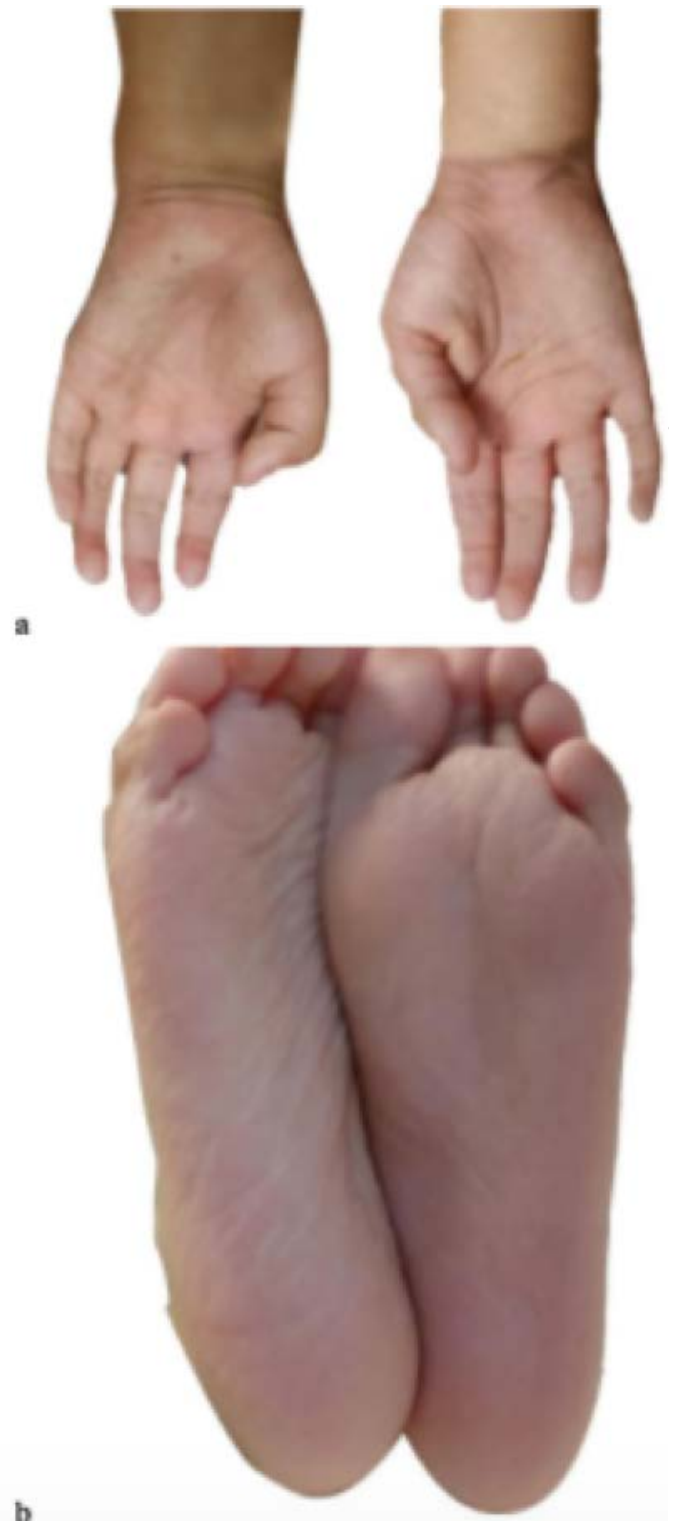

Figure 3. a) Front-view of patient's hands presenting camptodactyly and adducted thumbs, b) front-view of feet, showing adduction of toes.

METHODS

GTG-banded karyotype from peripheral blood cells cultured in RPMI-1640 supplemented and PB-Max™ GIBCO was performed. The 18 short arm FISH was done with orange spectrum (RP11-145B19) and the centromeric probe with green spectrum (CEP18). Subsequently, the patient's peripheral blood DNA was extracted to perform the SNP microarray analysis according to the CytoScan HD protocol of Affymetrix. Analyzed data, using the Chromosome Analysis Suite (ChAS) program, was reported and the informed consent was approved by the parents.

RESULTS

Cytogenetic analysis of the 25 blood cells, with a resolution of 550–600 bands, revealed the presence of a metacentric supernumerary marker chromosome. By its structure

and banding pattern, it corresponded to a short arm isochromosome in chromosome 18 (Figure 4). The FISH study corroborated the origin of the marker chromosome, by showing the two signals for the 18p subtelomere at orange spectrum, and an intermediate signal for the 18 centromere at green spectrum (Figure 5).

FISH was further analyzed in 100 interphase nuclei to verify the constitutive state of the marker chromosome; all had signals corresponding to the isochromosome. The microarray analysis showed a copy number gain of 18,385 Mb within the short arm of chromosome 18 (Figure 6). The data indicated the presence of four copies for each of the probes located between nucleotides 136,226 and 18,521,285 in the chromosomal bands of 18p11.32 to 18q11.1, which corresponded to more than 200 genes. These genomic abnormalities are identified as: 47,XY,+i(18)(p10)[25].ish;i(18)(p10)(RP11-145B19+,CEP18+,RP11-145B19+)[5].arr[hg19]; 18p11.32q11.1(136,226–18,521,285)x4.

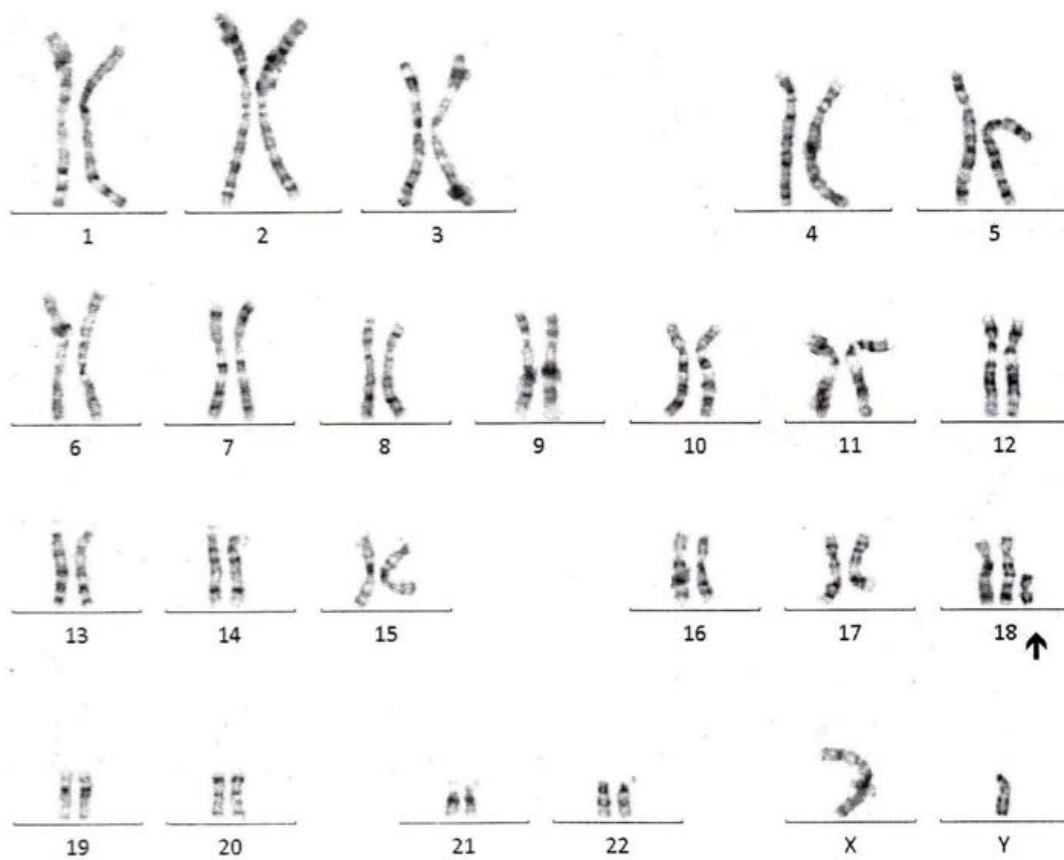


Figure 4. GTG-banded karyotype where the short arm isochromosome of chromosome 18, i(18)(p10) is shown.

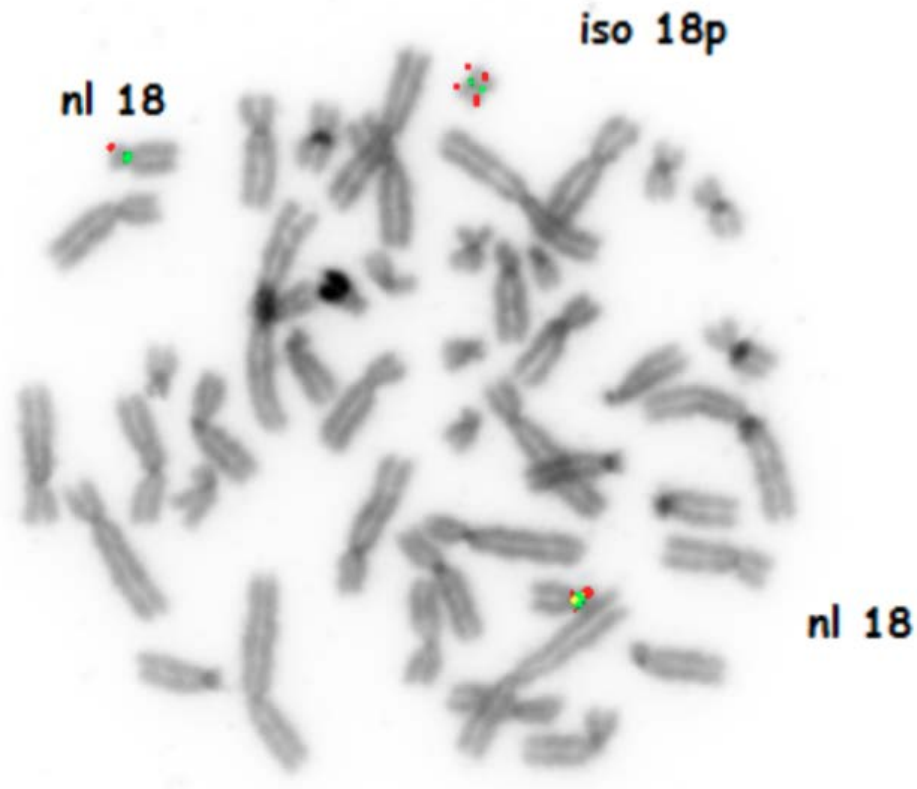


Figure 5. FISH over metaphase, isochromosome *i*(18p) shows two signals for short arm and one centromeric. Isochromosome 18p (iso 18p): shows centromere of 18 at green spectrum and subtelomeric region of 18p at orange spectrum. Normal chromosomes 18 (nl 18): show only a centromeric signal and a signal for short arm.

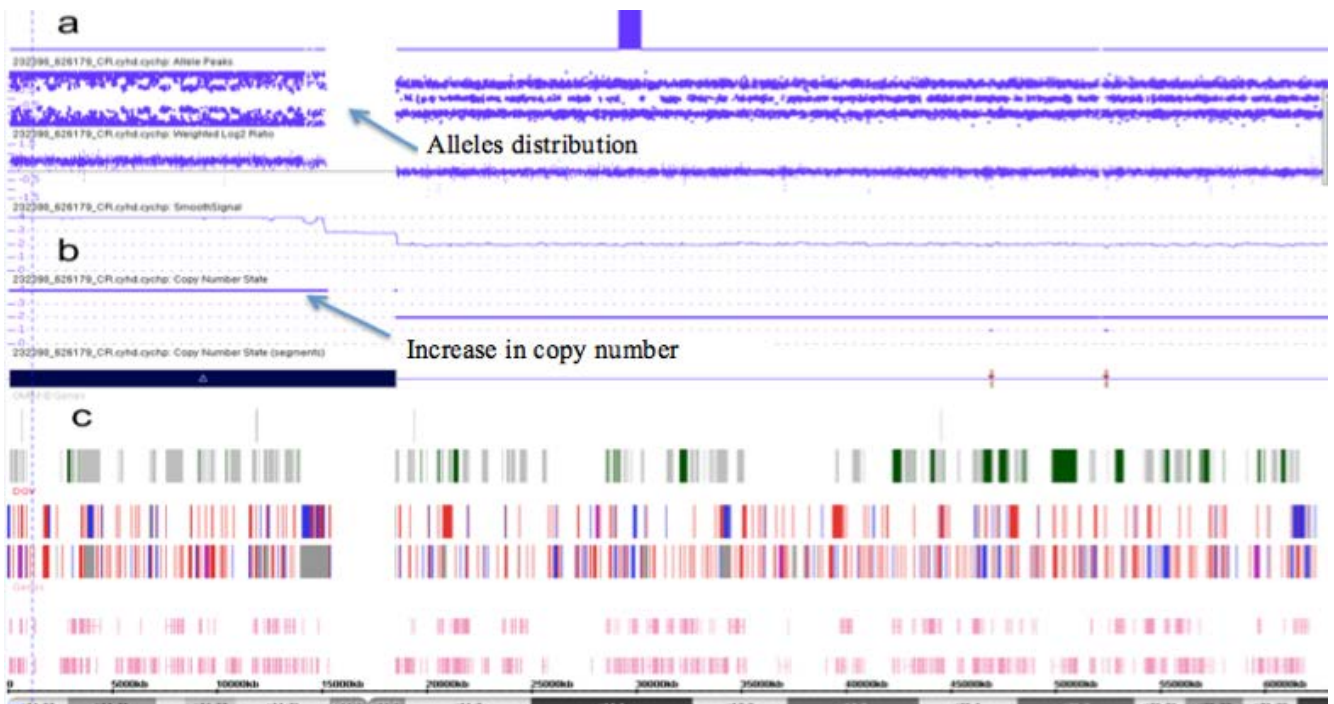


Figure 6. Analysis of the microarray in the ChAS software of chromosome 18, where the distribution of SNPs (a), increase in copy number (b), and genes and variants distributed throughout the chromosome (c) are observed.

METHODS

GTG-banded karyotype from peripheral blood cells cultured in RPMI-1640 supplemented and PB-Max™ GIBCO was performed. The 18 short arm FISH was done with orange spectrum (RP11-145B19) and the centromeric probe with green spectrum (CEP18). Subsequently, the patient's peripheral blood DNA was extracted to perform the SNP microarray analysis according to the CytoScan HD protocol of Affymetrix. Analyzed data, using the Chromosome Analysis Suite (ChAS) program, was reported and the informed consent was approved by the parents.

RESULTS

Cytogenetic analysis of the 25 blood cells, with a resolution of 550–600 bands, revealed the presence of a metacentric supernumerary marker chromosome. By its structure and banding pattern, it corresponded to a short arm isochromosome in chromosome 18 (Figure 4). The FISH study corroborated the origin of the marker chromosome, by showing the two signals for the 18p subtelomere at orange spectrum, and an intermediate signal for the 18 centromere at green spectrum (Figure 5).

FISH was further analyzed in 100 interphase nuclei to verify the constitutive state of the marker chromosome; all had signals corresponding to the isochromosome. The microarray analysis showed a copy number gain of 18,385 Mb within the short arm of chromosome 18 (Figure 6). The data indicated the presence of four copies for each of the probes located between nucleotides 136,226 and 18,521,285 in the chromosomal bands of 18p11.32 to 18q11.1, which corresponded to more than 200 genes. These genomic abnormalities are identified as: 47,XY,+i(18)(p10)[25].ish;i(18)(p10)(RP11-145B19+,CEP18+,RP11-145B19+)[5].arr[hg19]; 18p11.32q11.1(136,226-18,521,285)x4.

DISCUSSION

Chromosome 18 contains 76,117,153 bases, 243 known genes, and 45 loci implicated in genetic disorders, but there are not documented genes related to the 18p tetrasomy phenotype (Nusbaum *et al.*, 2005). Wei *et al.*, established

that aberrations of the whole short arm of chromosome 18 are negatively correlated with dosage effects in 18p⁻ (Wei *et al.*, 2015). In addition, several critical regions implicated in sensorial hearing loss and strabismus (1-1,192,031 region), as well as for scoliosis and kyphosis (1-2,931,532 region) can explain the clinical presentation.

The patient shares some of the more common clinical features in 18p tetrasomy, such as: high nasal bridge, micrognathia, prognathism, high arched palate, and low set/malformed ears. Also, feeding difficulties and musculoskeletal disorders were reported. Despite the lack? Unlike to the lack of sex predisposition, the literature reported a majority of female patients, whereas in this study, we present a male patient. In addition, the absence of spasticity and the normal height at birth differ from the reported in the literature (Table 1).

CONCLUSIONS

Advanced maternal age is known as a risk factor in the formation of an 18p tetrasomy 18. At the suspicion of this etiology, it is important to detect small supernumerary i(18p) by cytogenetic analysis, FISH, PCR, MLPA and, in some cases, array techniques. Parental testing is highly recommended.

Future studies? reports will allow to establish accurate data on its incidence and prognosis, raising awareness of its relevance to physicians. The latter will allow the patient to receive early and proper treatment, specifically for the ophthalmological and audiological features. Also, neurological, cardiac and gastrointestinal follow-ups would prevent the described clinical implications. It is important to give genetic counseling to the guardians.

BIBLIOGRAPHY

- Callen D.E, Freemantie C.J., Ringenbergs M.L., Baker E., Eyre H.J. (1990) The isochromosome 18p syndrome: Confirmation of cytogenetic diagnosis in nine cases by *in situ* hybridization. American Journal of Human Genetics 47, 3rd ser.: 493–498.
- Chen C., Lin C., Ko T., Chern S., Chen Y., Wu P., Wang W. (2014) Interphase FISH on uncultured amniocytes at repeat amniocentesis for rapid confirmation of low-

- level mosaicism for tetrasomy 18p. *Taiwanese Journal of Obstetrics and Gynecology* 53 (1): 126-128.
- Dutra A.N., Mancini T., Takeno S.S., Oliveira M.M., Kim C., Perez A.A., Melaragno M. (2012) Different Conformation of Two Supernumerary 18p Isochromosomes, One with a Concomitant Partial 18q Trisomy. *Cytogenetic and Genome Research Cytogenet Genome Res.* 138 (1): 1-4.
- Froland A., Holst G., Terslev E. (1963) Multiple anomalies associated with an extra small autosome. *Cylogenetics* 85: 99-106.
- Nusbaum C., Zody M.C., Borowsky M.L., Langer E.S. (2005) DNA sequence and analysis of human chromosome 18. *Nature* 438 (7068): 696.
- Plaiasu V., Ochiana D., Motei G., Georgescu A. (2011) A rare Chromosome Disorder- Isochromosome 18p syndrome. *MAEDICA a Journal of Clinical Medicine* 6 (2): 132-136.
- Zavala J., Ramirez M., Medina R., Heard P., Carter E., Crandall A., Escamilla M. (2009) Psychiatric syndromes in individuals with chromosome 18 abnormalities. *American Journal of Medical Genetics Part B: Neuropsychiatric Genetics*, 9999B.
- Wei J., Xie Y., He W., Liu W., Jian W., Chen M., Sun X. (2015) Clinical Outcome: A Monosomy 18p is Better than a Tetrasomy 18p. *Cytogenetic and Genome Research Cytogenet Genome Res* 144 (4): 294-298.
- Sebold C., Roeder E., Zimmerman M., Soileau B., Heard P., Carter E., Cody J.D. (2010) Tetrasomy 18p: Report of the molecular and clinical findings of 43 individuals. *American Journal of Medical Genetics Part A*, 152A (9): 2164-2172.
- Takeda K., Okamura T., Hasegawa T. (1989) Sibs with tetrasomy 18p born to a mother with trisomy 18p. *Journal of Medical Genetics* 26 (3): 195-197. doi:10.1136/jmg.26.3.195.